Obesity Surgery (2024) 34:1964–1968
https://doi.org/10.1007/s11695-024-07187-4

LETTER TO THE EDITOR

Guidelines for Management of Deep Vein Thrombosis (DVT) and Pulmonary Embolism (PE) Occurring After Metabolic Bariatric Surgery (MBS)

Chetan D. Parmar[1,2,3] · Daniel Moritz Felsenreich[4] · Paulina Salminen[5] · Nicola Di Lorenzo[6] · Gerhard Prager[4]

Received: 18 March 2024 / Revised: 18 March 2024 / Accepted: 19 March 2024 / Published online: 26 March 2024
© The Author(s), under exclusive licence to Springer Science+Business Media, LLC, part of Springer Nature 2024

Background

The reported incidence of deep vein thrombosis (DVT) is 1–3% and pulmonary embolism (PE) is 0.3–2% after metabolic and bariatric surgery (MBS) [1]. A recent systematic review reported the incidence of venous thromboembolism (VTE) to be 0.5% [2]. Regardless of the fact that MBS is very safe, VTE remains an important cause of morbidity and mortality after MBS [2, 3]. PE account for nearly 30% of mortality after MBS [2, 3]. There are no separate guidelines or management pathways for treatment of DVT and PE occurring after MBS. The aim of this letter is to provide the clinicians easy access to these in one place, when needed during emergency.

Causes

Obesity itself and laparoscopic surgery predispose to VTE [4]. Other medical causes predisposing VTE are immobilization, history of VTE, increased age, medications (contraceptive pills, hormone replacement therapy), smoking, heart failure and kidney disease. In rare cases inherited thrombophilia needs to be ruled out (e.g. factor V Leiden; prothrombin gene mutation; and deficiencies of antithrombin, protein C, or protein S). Also, acquired thrombophilia (polycythaemia vera, antiphospholipid antibodies) and elevated clotting factor VIII need to be considered [4, 5].

Signs/Symptoms of VTE

Classic symptoms of DVT include swelling, pain, warmth and redness in the involved extremity. Symptoms typical of PE include tachycardia, shortness of breath, sharp chest pain, dizziness and coughing/haemoptysis. Any of these symptoms along with extremity pain or swelling increases the likelihood of PE [4, 5].

Diagnosis

DVT

After thorough clinical examination, 'Wells scoring' is used to estimate the clinical probability of DVT [6]. The probability of 'likely' or 'unlikely' DVT guides to further investigations including D-dimer and/or compression ultrasonography (USG) of the lower limbs. The negative predictive value of D-dimer is high. If these tests are not available, a computed tomography (CT) scan is performed. In patients with poor kidney function or allergy to contrast, a magnetic resonance imaging (MRI) is suggested (Summarised in Fig. 1 flowchart).

PE

Blood gases and chest x-ray are performed to rule out other causes. Validated prediction tools like the revised Geneva rule or Wells score are used [7–9]. Depending on probability of 'likely' or 'unlikely' PE, a D-dimer test and/or a spiral CT pulmonary angiography (CTPA) is performed. If CTPA is not available or contraindicated, a ventilation/perfusion

✉ Chetan D. Parmar
drcparmar@gmail.com

1 Whittington Hospital, London N19 5NF, UK
2 University College London, London, UK
3 Apollo Hospitals, Chennai, India
4 Department of Surgery, Vienna Medical University, Vienna, Austria
5 Department of Surgery, University of Turku, Turku, Finland
6 Department of Surgical Sciences, University of Tor Vergata, Policlinico Tor Vergata, Rome, Italy

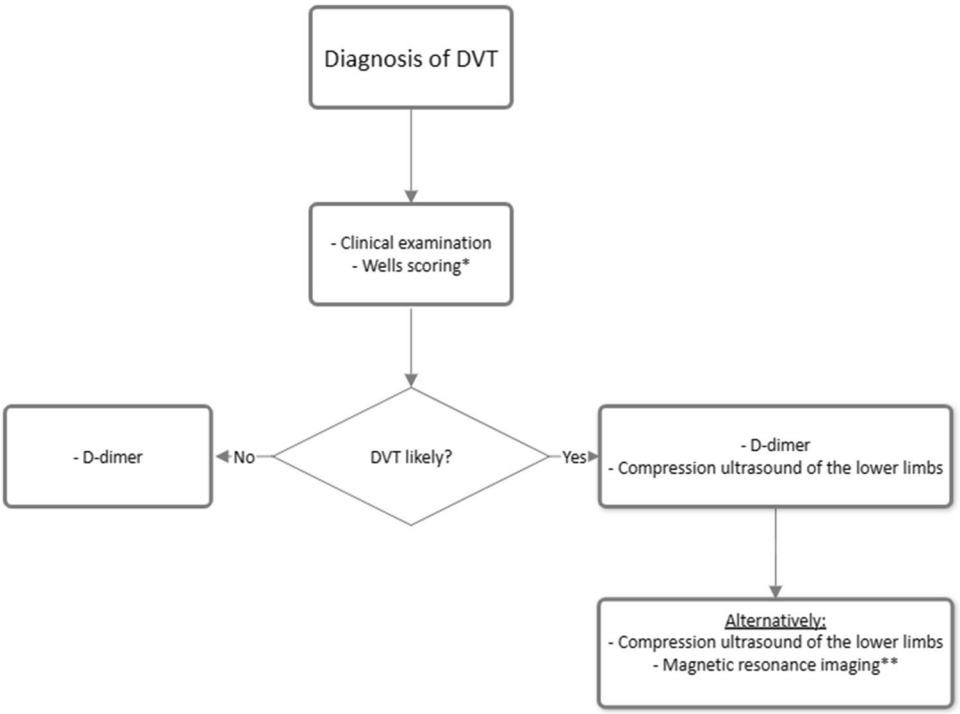

Fig. 1 Diagnosis of DVT. Abbreviations: DVT, deep-vein thrombosis. A single asterisk (*) indicates clinical judgement if DVT is likely or unlikely. Double asterisks (**) indicate in patients with poor kidney function

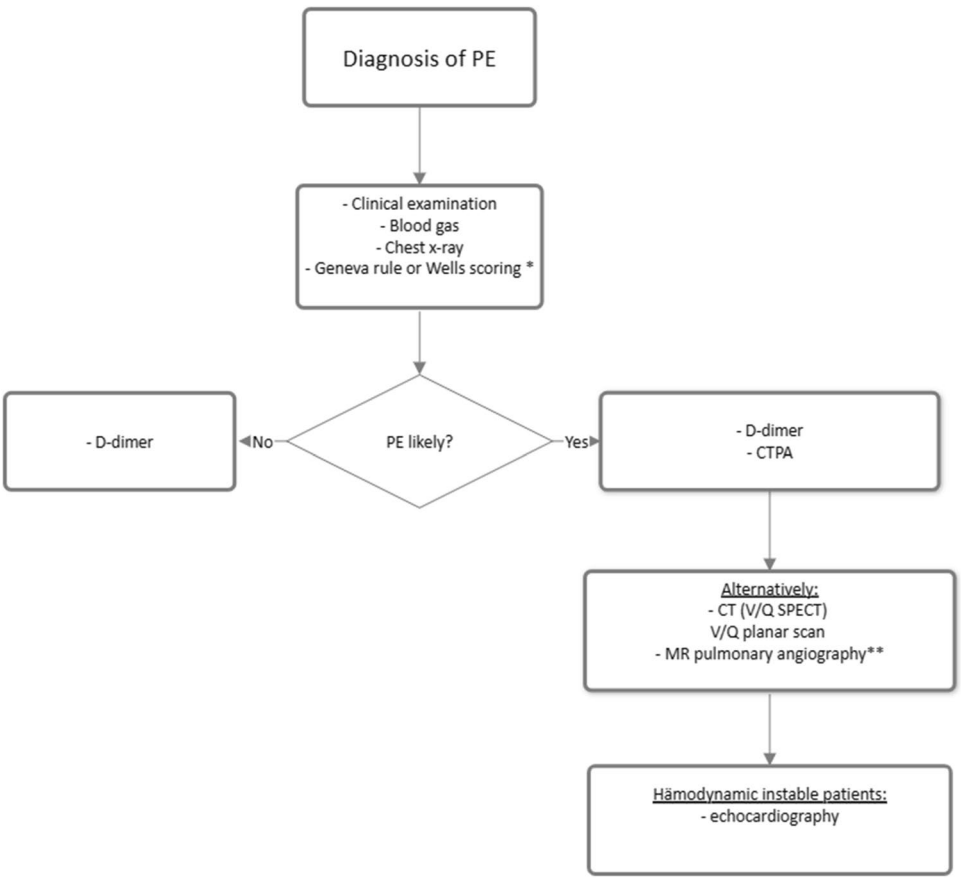

Fig. 2 Diagnosis of PE. Abbreviations: PE, pulmonary embolism; V/Q SPECT, ventilation/perfusion single photon emission computed tomography; CPTA, spiral CT pulmonary angiography. A single asterisk (*) indicates clinical judgement if DVT is likely or unlikely. Double asterisks (**) indicate in patients with poor kidney function

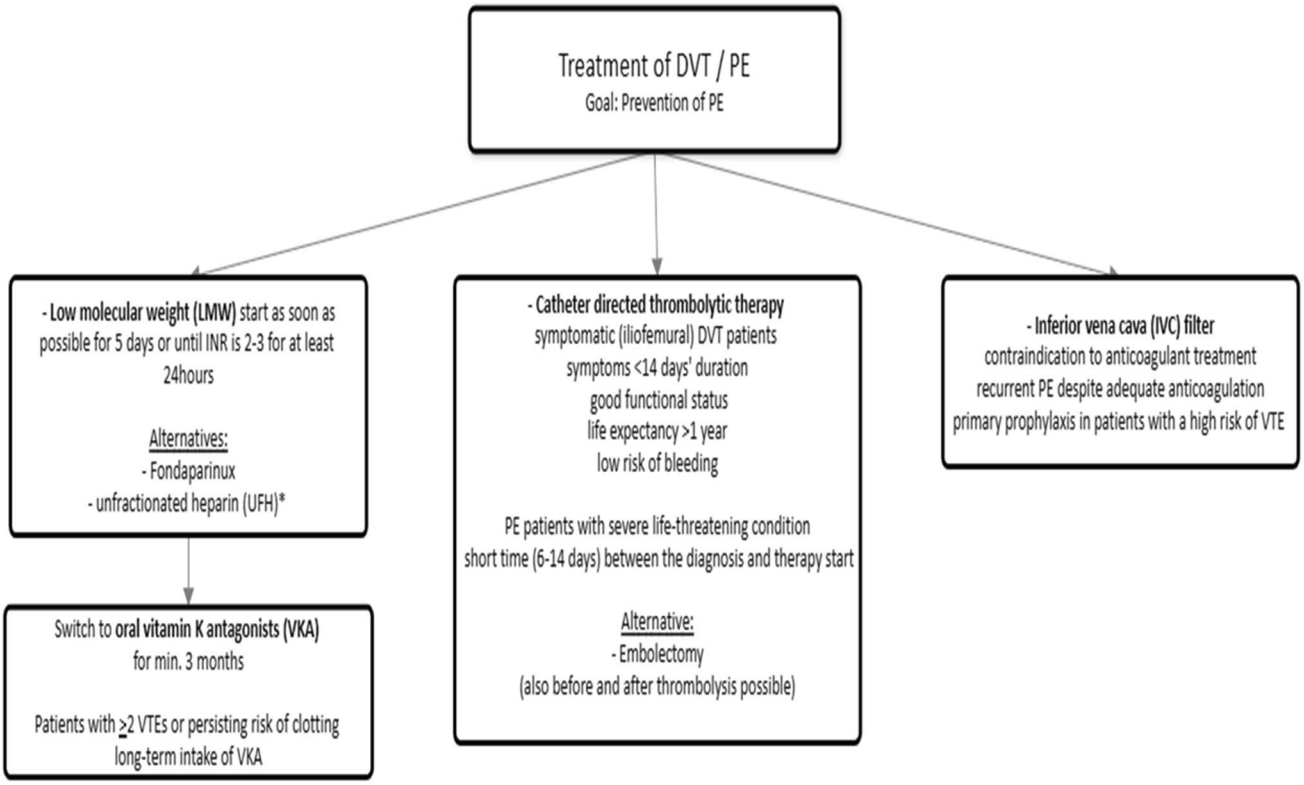

Fig. 3 Treatment of DVT and PE. Abbreviations: DVT, deep-vein thrombosis; PE, pulmonary embolism

single photon emission CT (V/Q SPECT) scan or a V/Q planar scan is performed. MR pulmonary angiography is an alternative. In patients presenting with haemodynamic instability, echocardiography (ECHO) can help [7, 8].

With history of recurrent VTE and/or a family history of VTE, other inherited causes are investigated (Summarised in Fig. 2 flowchart).

Treatment of DVT/PE

The aim of treatment is to prevent the clot from becoming larger, prevent new clot formation and prevent long-term complications.

In treating DVT, the main goal is to prevent a PE. Patients should be offered interim anticoagulation therapy if diagnostic investigations are expected to take > 4 hours from the time of first clinical suspicion in case of DVT (to prevent PE) and > 1 hour in case of PE (to reduce risk of mortality). The modalities of treatment include the following:

Anticoagulation Therapy:
Low-molecular weight (LMW) heparin (enoxaparin, dalteparin, tinzaparin) is favoured [2, 5]. Fondaparinux is an alternative [5].

In cases with severe kidney failure (eGFR < 30 ml/min/1.73 m^2) or with increased risk of bleeding, unfractionated heparin (UFH) can be used and dose adjusted [5].
LMWH/fondaparinux / UFH is administered as soon as possible and is continued for at least 5 days or until the international normalised ratio (INR) is 2–3 for at least 24 h, whichever is longer. Then, the patient is switched to oral vitamin K antagonists (VKA) (warfarin), if not contraindicated, which are routinely continued for a minimum of 3 months (if reversible risk factor contributing to DVT, e.g. MBS was the only provoking factor for VTE). With LMWH as initial treatment and oral anticoagulation delivering INR of 2–3, the rate of major bleeding at 3 months is ≤ 3% and mortality is ≤ 0.5% [5].
In patients with ≥ 2 episodes of VTE, antiphospholipid syndrome, active cancer or if a risk factor for clotting persists, VKA is continued long-term [2, 4, 7].
There is a paucity of evidence for the use of direct oral anticoagulants (DOAC) (rivaroxaban, apixaban, dabigatran, edoxaban) in bariatric practice [10].
The validated risk stratification tools predicting morbidity and mortality after diagnosed PE are the PE Severity Index (PESI), Geneva score and Simplified-PESI (sPESI) score. Low-risk patients can be managed in an outpatient setting [2, 4].

Thrombolytic Therapy:
Catheter-directed thrombolytic therapy is used for patients with symptomatic iliofemoral DVT who have symptoms < 14 days' duration, good functional status, life expectancy > 1 year and a low risk of bleeding.
PE with severe life-threatening condition [systolic blood pressure (SBP) < 90 mmHg or a decrease in the SBP ≥ 40 from baseline] is a widely accepted indication for systemic thrombolysis (alteplase, streptokinase) as it reduced short-term mortality [10]. Ideally, there should be a short time (6–14 days) between the diagnosis of VTE and the start of thrombolytic therapy. Beware risk of increased major bleeding [11].

Percutaneous Mechanical Thrombectomy:
If thrombolytic therapy fails or is not an option, embolectomy may be attempted. It can also be done before thrombolysis to reduce the size of the clot, or after thrombolysis, if the thrombus persists. It can be used in PE in an immediate postoperative scenario and can be combined with ECMO [2, 7, 10, 11].

Inferior Vena Cava (IVC) Filter:
Potential indications for IVC filter include VTE with absolute contraindication to anticoagulant treatment (recent surgery, a stroke caused by bleeding, significant bleeding in another area), recurrent PE despite adequate anticoagulation (after considering alternative options of increasing target INR to 3–4 for long-term oral anticoagulant therapy or switching treatment to LMWH), and primary prophylaxis in patients with a high risk of VTE [11]. Complications associated with the IVC filters seem to outweigh a potential benefit; hence, its routine use in not recommended before MBS [12, 13]. The overall treatment is summarised in Fig. 3 flowchart.

Follow-up

The patient should be provided with the anticoagulant information booklet and should always carry their alert card. They should be followed-up to avoid risk of recurrence as well as VTE and anticoagulation-related complications. Patients with proximal DVT can develop post-thrombotic syndrome (PTS) in 30–50% cases [12]. Patients with PE have incidence of 0.1–9% of chronic thromboembolic pulmonary hypertension (CTEPH). First, VTE provoked by major surgery has 1% chance of recurrence rate at 1 year after stopping anticoagulation. This can increase to 3% after 5 years [12, 13].

Prevention

Hospital in-patients should receive mechanical prophylaxis (compression stockings, intermittent pneumatic compression). Early post-surgical ambulation should be encouraged. In addition to mechanical prophylaxis, some form of chemoprophylaxis ought to be prescribed [12, 13]. The duration of pharmacoprophylaxis can be guided by validated thrombosis risk assessment tools: Caprini thrombosis risk assessment tool [14] or Cleveland clinic risk calculator [1]. In this era, when bariatric medical tourism is popular and some patients travel long distances postoperatively after MBS, they should be vigilant and follow recommendations [5, 15].

Declarations

Ethical Approval This type of study does not need ethical approval.

Competing Interests The authors declare no competing interests.

References

1. Aminian A, Andalib A, Khorgami Z, et al. Who should get extended thromboprophylaxis after bariatric surgery? A risk assessment tool to guide indications for post-discharge pharmacoprophylaxis. Ann Surg. 2017;265(1):143–50.
2. Mazzolai L, Aboyans V, Ageno W. Diagnosis and management of acute deep vein thrombosis: a joint consensus document from the European Society of Cardiology working groups of aorta and peripheral vascular diseases and pulmonary circulation and right ventricular function. Eur Heart J. 2018;39(47):4208–18.
3. Morino M, Toppino M, Forestieri P, et al. Mortality after bariatric surgery: analysis of 13,871 morbidly obese patients from a national registry. Ann Surg. 2007;246:1002–7.
4. Giannis D, Geropoulos G, Kakos CD, et al. Portomesenteric vein thrombosis in patients undergoing sleeve gastrectomy: an updated systematic review and meta-analysis of 101,914 patients. Obes Surg. 2023;33(10):2991–3007.
5. https://www.uptodate.com/contents/deep-vein-thrombosis-dvt-beyond-the-basics. Last accessed on 12th March 2024.
6. Wells PS, Anderson DR, Rodger M, et al. Evaluation of D-dimer in the diagnosis of suspected deep-vein thrombosis. N Engl J Med. 2003;349(13):1227–35.
7. Konstantinides SV, Meyer G, Becattini C, et al. 2019 ESC Guidelines for the diagnosis and management of acute pulmonary embolism developed in collaboration with the European Respiratory Society (ERS): the Task Force for the diagnosis and management of acute pulmonary embolism of the European Society of Cardiology (ESC). Eur Heart J. 2020;41(4):543–603.
8. Howard LSGE, Barden S, Condliffe R, et al. British Thoracic Society Guideline for the initial outpatient management of pulmonary embolism (PE). Thorax. 2018;73:ii1–29.
9. Wells PS, Anderson DR, Rodger M, et al. Derivation of a simple clinical model to categorize patients probability of pulmonary embolism: increasing the models utility with the SimpliRED D-dimer. Thromb Haemost. 2000;83(3):416–20.

10. Rottenstreich A, Barkai A, Arad A, et al. The effect of bariatric surgery on direct-acting oral anticoagulant drug levels. Thromb Res. 2018;163:190–5.
11. Quezada CA, Bikdeli B, Barrios D, et al. Meta-analysis of prevalence and short-term prognosis of hemodynamically unstable patients with symptomatic acute pulmonary embolism. Am J Cardiol. 2019;123(4):684–9.
12 Aminian A, Vosburg RW, Altieri MS, et al. American society for metabolic and bariatric surgery clinical issues committee. The American Society for Metabolic and Bariatric Surgery (ASMBS) updated position statement on perioperative venous thromboembolism prophylaxis in bariatric surgery. Surg Obes Relat Dis. 2022;18(2):165–74.
13. Tran HA, Gibbs H, Merriman E, et al. New guidelines from the Thrombosis and Haemostasis Society of Australia and New Zealand for the diagnosis and management of venous thromboembolism. Med J Aust. 2019 Mar;210(5):227–235. Erratum in: Med J Aust. 2019 Jul;211(2):94. Erratum in: Med J Aust. 2020 Feb;212(3):108.
14 Caprini JA. Thrombosis risk assessment as a guide to quality patient care. Dis Mon. 2005;51(2–3):70–8.
15. Parmar CD, McCluney SJ, Rodriguez N, et al. A global survey by the international federation for the surgery of obesity and metabolic disorders (IFSO) on perceptions of bariatric medical tourism (BMT) by health professionals: guidelines from IFSO for BMT. Obes Surg. 2021;31(4):1401–10.

Publisher's Note Springer Nature remains neutral with regard to jurisdictional claims in published maps and institutional affiliations.